

# LONG-TERM RESULTS OF REPLANTATION OF THE PROXIMAL FOREARM FOLLOWING AVULSION AMPUTATION

ANDREA ATZEI, M.D.,\* MARCO PIGNATTI, M.D., CARLA MARIA BALDRIGHI, M.D., MASSIMO MARANZANO, M.D., AND LANDINO CUGOLA, M.D.

This study reports on the long-term functional outcomes of a homogeneous series of 10 cases of successful replantation of an avulsed proximal forearm and its acceptance on the part of patients. After a minimum follow-up of 3 years (average, 4.7 years), muscular and sensory recovery was evaluated with the Medical Research Council scale, and global function according to the demerit score system of Chen (China Med 5:392–397, 1967). Subjective evaluation and patient satisfaction were investigated by means of a questionnaire. One patient was classified as grade 2, 4 patients as grade 3, and 5 patients as grade 4 according to Chen (China Med 5:392–397, 1967). However, in spite of the poor objective results, patient satisfaction was obtained in 90% of cases, and the replanted extremity was considered of help for common activities of daily living. In conclusion, replantation of an avulsed proximal forearm should be considered only in patients who are strongly motivated to maintain body integrity, and who are aware of the expected functional limitations. © 2005 Wiley-Liss, Inc.

Since microsurgical replantation of amputated segments of the upper extremity became a reality more than 30 years ago, continuous progress in the treatment of amputating injuries suggests that factors influencing indications, long-term functional results, and improvement of the patient's quality of life should be reevaluated. Reports concerning the management of amputating injuries of the upper limb proximal to the wrist are often based on clinical series including patients with highly variable levels of amputation and disparate traumatic mechanisms.<sup>1–6</sup>

In particular, with reference to the avulsed proximal forearm, few reports can be found in the literature dedicated to a thorough evaluation of reconstructive problems and results of replantation, with the exception of the position of clean-cut injuries.

The aim of this study is to analyze functional outcomes and patients' perception of the benefits of a homogeneous series of replantations following avulsion amputation at the level of the proximal forearm.

## MATERIALS AND METHODS

Clinical data on 673 upper limb replantations performed at our department between 1985–1995, were reviewed to find patients who fulfilled the following criteria: 1) amputation consequent to a true avulsion injury; 2) level of amputation between the elbow joint

and the insertion of the pronator teres on the radius (level 6 according to the classification suggested by the IFSSH Committee on Microsurgery,<sup>7</sup> or type III traction avulsion amputation according to the classification proposed by Chuang et al.<sup>6</sup>); and 3) minimum follow-up of 3 years from replantation.

Ten patients were found whose forearms were replanted successfully.

All patients were male, their mean age was 40.1 years at time of trauma, and the dominant side was involved in all cases. Records and surgical procedures are summarized in Table 1.

All patients received perioperative broad-spectrum antibiotics and were operated on under general anesthesia. The wounds were irrigated, and the bony ends were shortened (4 cm on average) in order to remove devitalized extremities and allow for direct end-to-end soft-tissue repair.

All nonviable or questionably viable soft tissues were extensively debrided, lacerated muscle bellies were repaired by gross epimyseal suture, and avulsed tendons required reinsertion into the estimated original muscle.

Restoration of vascular supply required the use of interpositional vein grafts especially for venous repair, but once blood flow was reestablished, it was maintained without any major circulatory complications.

Primary nerve reconstruction was attempted in all cases, giving the major priority to the median and radial nerves.

A mean of 3.1 secondary procedures per patient was performed.

The overall duration of treatment was 23.6 months on average (range, 11–34 months).

Follow-up evaluation was performed after a minimum of 3 years following replantation. Functional recovery was evaluated according to the criteria of Chen<sup>8</sup> (Table 2). Muscular and sensory recovery was

Hand Surgery Unit, Azienda Ospedaliera Universitaria di Verona, Policlinico "G.B. Rossi," Verona, Italy

Massimo Maranzano, M.D., is a former Fellow in Microsurgery, Department of Maxillofacial Surgery, Regional Hospital, Udine, Italy.

\*Correspondence to: Andrea Atzei, M.D., Unità di Chirurgia della Mano, Ospedale Policlinico "G.B. Rossi," P. le L.A. Scuro 10, 37100 Verona, Italy. E-mail: andreatzei@email.it

Received 28 February 2005; Accepted 8 March 2005

DOI: 10.1002/micr.20131

**Table 1.** Patients' Data and Surgical Procedures\*

Patient	Age at time of trauma	Mechanism of trauma*	Associated injuries	Minimum ischemia time	Bone fixation	Artery reconstruction	Vein reconstruction	Nerve reconstruction	Secondary procedures	Total duration of treatment
1	21	R	Head injury, mandibular fracture	8.5	K-wire	Rad + Uln	3, vein graft	Post. Int. + U	1 Skin graft and skin expander	34
2	27	I		4.5	Plate	Ulnar	3	M + U	2. Plating of Radius-Ext.Fix. of ulna 3. Sural nerve graft to median nerve 4. Reconstruction of thumb opposition by arthrodesis and tendon transfers 1 Plate removal for osteomyelitis of the ulna and external fixation 2 Debridement and bone grafting for nonunion of the ulna 3 Tenolysis and tendon transfers 1 Skin grafts 2 Tenolysis and tendon transfers 3 Arthrodesis	32
3	31	A		5.5	Ext. Fix.	Rad + Uln	4	M + U	1 External fixation of radius and ulna	25
4	34	I		5.0	K-wire	Rad + Uln	4	M + U +Post. Int.	1 External fixation of radius and ulna	45
5	37	I		4.0	K-wire	Rad + Uln	4	M	2 Skin grafts 3 Tenolysis and tendon transfers	21
6	43	I		5.0	Plate	Radial	3	M, graft from U	3 Tenolysis and tendon transfers 4. Constrained total elbow replacement 5 Reconstruction of thumb opposition by arthrodesis and tendon transfers	17
7	46	I		4.5	Plate	Rad + Uln	3, vein graft	M + U	1 Plating of ulna 2 Plate removal for osteomyelitis of ulna 3 Debridement, bone grafting and plating for nonunion of the ulna 4. Reconstr of thumb opposition by arthrodesis and tendon transfers	29
8	47	A	Thoracic trauma	6.5	Ext. Fix.	Rad + Uln	3, vein graft	M + U	1 Wrist arthrodesis 2 Tendon transfer 3 Arthrodesis for thumb opposition	22
9	52	I		4.0	K-wire	Rad + Uln	3	M + U	1 Skin grafts 2 Bone grafting for nonunion of radius 3 Tenolysis	23
10	63	I	Head injury amp little finger	6.5	Ext. Fix.	Rad (vein graft)	3	None	1 Skin grafts 2 Skin expander	11
									1 External fixation of radius and ulna 2 Flexor tenolysis 1 Skin grafts and Abdominal flap 2 Debridement of osteomyelitis	

\*Ext. Fix., external fixation; M, median nerve; Post. Int., posterior interosseous nerve; Rad, radial artery; U, ulnar nerve; Uln, ulnar artery.

**Table 2.** Chen's Scoring System for Evaluation of Functional Outcome After Replantation of Amputated Extremity<sup>8</sup>

Chen's score	Use	Joint mobility	Sensibility	Muscle power
1	Original occupation	≥ 60%	Largely restored	4 or 5
2	Gainful employment	≥ 40%	Median and ulnar territories	3 or 4
3	Independent in daily life	≥ 30%	Poor but useful	
4	No useful function			

**Table 3.** Patient data at follow-up\*

Patient	Muscular recovery		Sensory recovery		Chen's score	Patient's evaluation		Replant vs Prost	Recomm
	Extrinsic	Intrinsic	Median nerve	Ulnar nerve		ADL	Satisfaction		
1	M3	M0	S3	S3	3	All activities	Better than expected	Yes	Yes
2	M3	M1–M2	S4	S2	3	Most activities	Better than expected	Yes	Yes
3	M1–M2 distrectual	M0	S1	S0	4	A little	Somewhat satisfied	Yes	Yes
4	M1–M2 distrectual	M0	S0	S0	4	A little	Somewhat satisfied	Yes	Yes
5	M1–M2 distrectual	M0	S2	S2	4	Many activities	Somewhat satisfied	Yes	Yes
6	M0	M0	S0	S0	4	A little	Not satisfied	Yes	Yes
7	M3	M0	S3	S2	3	Most activities	Better than expected	Yes	Yes
8	M4	M3	S4	S4	2	All activities	Better than expected	Yes	Yes
9	M2 distrectual	M0	S3	S0	3	Most activities	Fully satisfied	Yes	Yes
10	M0	M0	S0	S0	4	Many activities	Somewhat satisfied	Yes	Yes

\*Subjective evaluation of function and patient's satisfaction were investigated by the following questionnaire:<sup>10</sup>

ADL: Can you use your extremity for common activities of daily living?

1) Not at all; 2) A little; 3) For many activities; 4) For most activities; 5) For all activities.

Satisf: How satisfied are you with your replanted extremity?

1) Not satisfied; 2) Somewhat satisfied; 3) Fully satisfied; 4) Better than expected; 5) No difference from before surgery.

Replant vs. Prost: Do you think your extremity is better than a prosthesis fitted on the amputation stump? Yes/No

Recomm: Would you recommend this procedure to others with a similar injury? Yes/No

evaluated according to the Medical Research Council (MRC) scale,<sup>9</sup> separately for extrinsic and intrinsic muscle groups, and median and ulnar innervated territories. Subjective evaluation of function and patient satisfaction were investigated by the questionnaire of Russell et al.<sup>10</sup> and reported in Table 3.

## RESULTS

Patients were evaluated at an average follow-up of 56.4 months. Results of follow-up evaluations are summarized in Table 3. Details of muscular and sensory recovery are shown in Figure 1. Repair of the median nerve could not be performed in one (patient 10) of the three cases rated as S 0 for sensory recovery in the territory of the median nerve. Repair of the ulnar nerve could not be performed in 2 (patients 6 and 10) of the 5 cases rated as S 0 for sensory recovery in the territory of the ulnar nerve.

According to the scoring system of Chen,<sup>8</sup> 1 patient was classified as grade 2, 4 patients as grade 3, and 5 patients as grade 4. Useful recovery of extrinsic muscles occurred in 4 cases, although limited by a distrectual pattern of recovery, while intrinsic muscle recovery was useful in only one case. Protective digital sensitivity resumed in 5 cases in the median nerve territory, and in 2

cases in the ulnar nerve territory. Only one patient (patient 8) achieved grade 2 of Chen.<sup>8</sup> In this patient, restoration of muscle strength was good for both the extrinsic and intrinsic muscles (Fig. 2), as well as restoration of some discriminative sensitivity.

Sensory recovery of the 4 patients at grade 3 was rather modest (average, 2.5). No recovery of the intrinsic muscles was detectable, while recovery of the extrinsic muscles occurred in a distrectual, randomized fashion, and was limited to some muscle groups without a predictable topography. Patients reported that the replanted upper limb was of help in accomplishing almost all activities of daily living and only light bimanual work (Fig. 3).

The remaining 5 patients were classified as grade 4.

There was some correlation between functional outcome measured by the score of Chen<sup>8</sup> and the patients' evaluation, as shown in Figure 4.

One patient was not satisfied, 5 were "somewhat" to "fully satisfied," and the remaining 4 considered the final result better than expected as compared with the severity of the initial injury.

All patients considered themselves self-sufficient in most activities of daily living (e.g., personal care, dressing, eating).

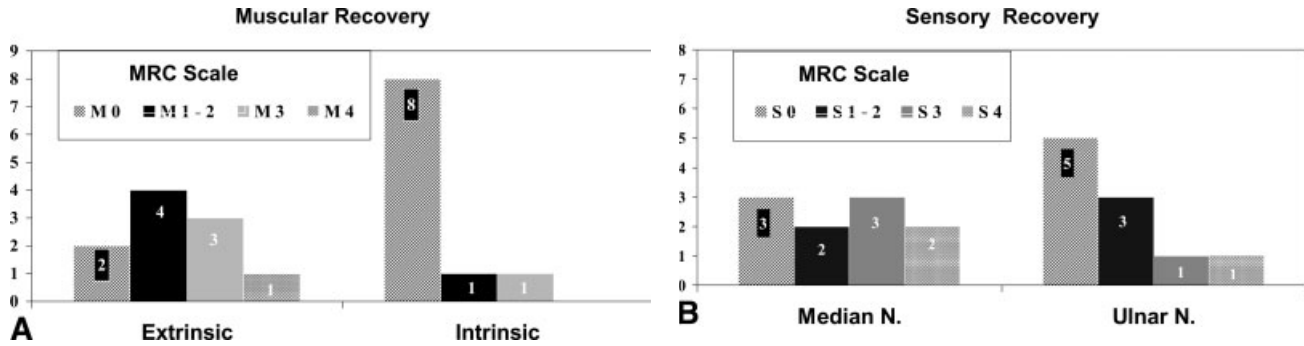
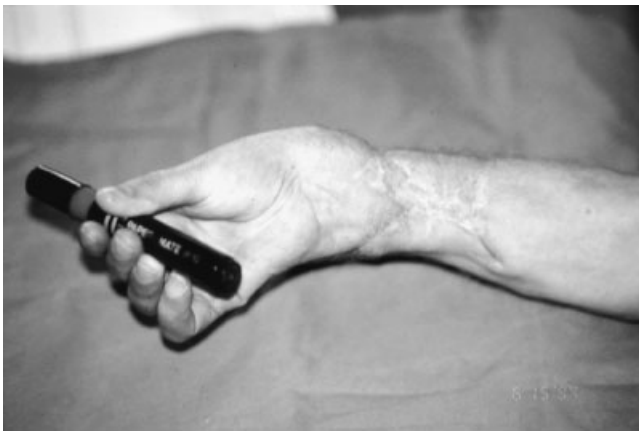

Figure 1. Muscular (a) and sensory (b) recovery were evaluated according to MRC scale,<sup>7</sup> separately for extrinsic and intrinsic muscle groups and for territories innervated by median and ulnar nerves, respectively.



A



B

Figure 2. Functional result of patient 8, achieving grade 2 of Chen<sup>8</sup> at 8 years of follow-up (a, b).

None of the patients asked for reamputation during the early follow-up. At the late follow-up, all of them considered themselves self-sufficient in most activities of daily living, and 7 of them judged the function of the replanted extremity as acceptable. One patient was not

satisfied; 5 were “somewhat” to “fully satisfied.” The remaining 4 considered the final result better than expected. All patients preferred the replanted limb, though almost functionless, to prosthesis, and would have recommended replantation to others with a similar injury.

## DISCUSSION

For anatomical reasons, replantation at the proximal forearm yields the lowest success rate and poorest functional outcomes.<sup>1</sup>

Forearm avulsion results from a combination of crushing and tearing forces associated with twisting and bending, leading to a severance pattern highly variable and unpredictable for site and severity of tissue damage.

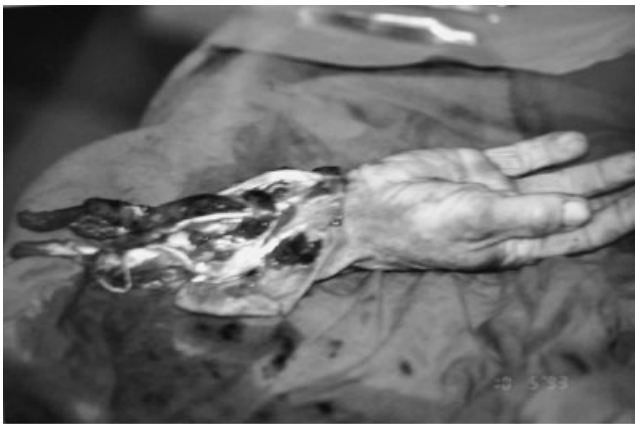
Since the majority of vascular pedicles and motor branches supplying the 20 muscle bellies located in the forearm arise within 10 cm from the antecubital crease,<sup>10–13</sup> once avulsion occurs at this site, the neurovascular tree at the site of injury is beyond repair, even when anastomosis or grafting of the main vessels and nerves restores vascularization and innervation to the distal replanted segment. As a consequence, large areas of ischemic and crushed muscle may develop infections or become fibrotic. In addition to muscle fibrosis, non-reparable tearing of the motor branches and extensive nerve laceration are responsible for muscle dysfunction and poor distal sensory recovery of the replanted upper forearm.

Although the series published in the literature are vastly heterogeneous regarding the mechanism of amputation, it appears that, after replantation of the proximal forearm, a “functional extremity” was achieved in about 30% of cases.<sup>10,14</sup>

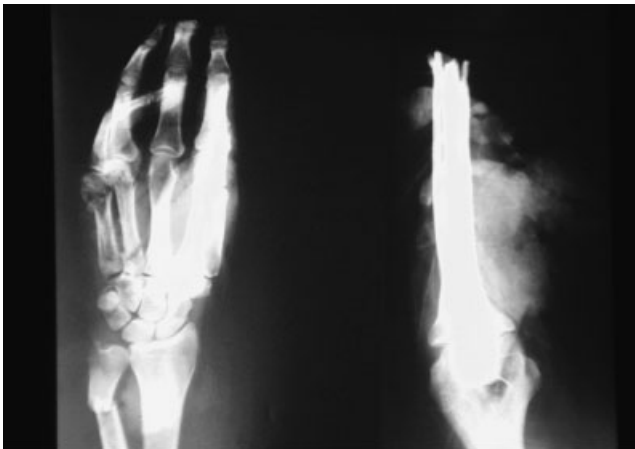In the present series of avulsion amputations, despite the high rate of reoperations performed to improve function of the replanted forearm, a “functional extremity” (grade 2 or less of Chen<sup>8</sup>) was achieved only in 1 case out of 10.



A



B

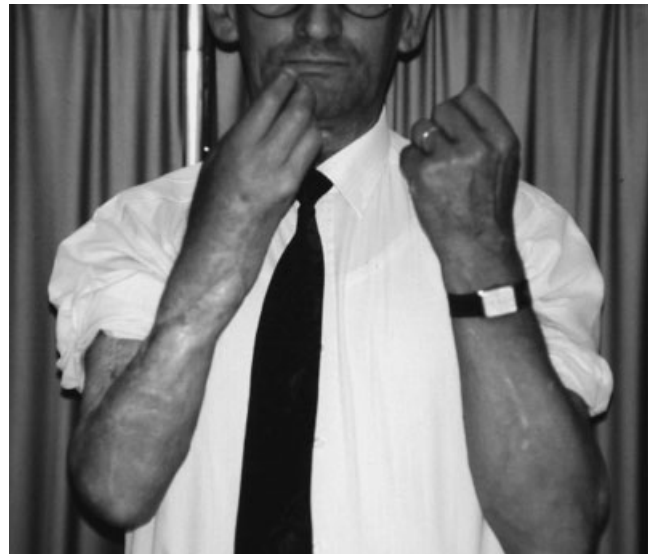

C

However, in spite of a disappointing objective recovery of muscular and sensory function, the degree of patients' satisfaction was surprisingly good. This discrepancy can be explained by emotional factors, mainly preservation of body integrity, and explains the growing pressure



D



E

Figure 3. Patient 10. Preoperative clinical pictures (a, b) and X-rays (c). Clinical appearance at follow-up, 4 year after replantation (d, e). Replanted upper limb scored grade 3 of Chen<sup>8</sup> and was of little help to accomplish activities of daily living, but satisfied this 67-year-old retired man's expectations.

toward replantation exerted on surgeons from patients and their relatives.

In 1994, Fukui and Tamai<sup>15</sup> reported that 56% of Japanese surgeons performed replantations upon request; it may be assumed that this rate is similar in Europe. Understanding of a patient's personality and motivation, along with a clear explanation of the difficulties in resuming an "at best" limited functional recovery of the replanted extremity, may help to improve a patient's acceptance of prolonged treatment. It may also explain a patient's satisfaction even in the face of an objectively functional failure.

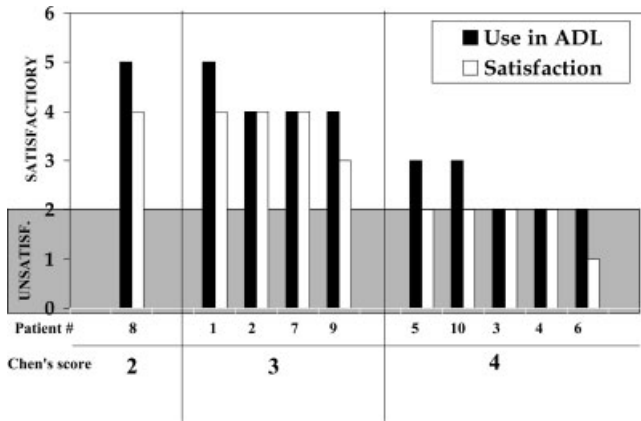


Figure 4. Patients' evaluation expressed according to use of extremity in activities of daily living (ADL) (solid columns) and subjective satisfaction (open columns). Patients were further divided according to score of Chen.<sup>8</sup>

A formal cost-benefit analysis comparing replantation with amputation and prosthetic fitting was not performed in this study. However, in cases of primary amputation, there may be some advantages in the performance of common duties such as eating, dressing, and personal care, only when an amputation stump longer than 10 cm can be preserved and a below-elbow prosthesis can be worn. Otherwise, an above-elbow prosthesis should be applied, with rather modest cosmetic and functional results and a high rate of prosthetic rejection.<sup>16</sup> Furthermore, in terms of social costs, one may consider that the earlier advantage of low operative costs could be lost over time due to expenses arising from prosthetic renewal and disability living allowance, to be paid at least until retirement.

## CONCLUSIONS

According to the results of this study, replantation of an avulsed proximal forearm yields limited functional results.

Following avulsion amputation at the level of the proximal forearm, indications for replantation should be considered only in patients who are strongly motivated to maintain body integrity. Patients must be pre-

pared for long postoperative treatment and several further operations, and must be aware that the expected functional result might be rather poor.

## REFERENCES

1. Wang SH, Young KF, Wei JN. Replantation of severed limbs: clinical analysis of 91 cases. *J Hand Surg [Am]* 1981;6:311-317.
2. Brunelli G, Vigasio A, Battiston B, Stefani G. Arm and forearm replantation. In: Brunelli G, editor. *Textbook of microsurgery*. Milan: Masson; 1988; p 473-440.
3. Caroli A, Adani R, Castagnetti C, Squarzina PB, Pancaldi G, Cristiani G. Replantation and revascularization of large segments of the hand and forearm. *Ital J Orthop Traumatol* 1991;17:433-447.
4. Goldner RD, Nunley JA. Replantation proximal to the wrist. *Hand Clin* 1992;8:413-425.
5. Daoutis NK, Gerostathopoulos N, Efstathopoulos D, Misitzis D, Bouchlis G, Anagnostou S. Major amputation of the upper extremity. *Acta Orthop Scand [Suppl]* 1995;264:7-8.
6. Chuang DC, Lai JB, Cheng SL, Jain V, Lin CH, Chen HC. Traction avulsion amputation of the major upper limb: a proposed new classification, guidelines for acute management, and strategies for secondary reconstruction. *Plast Reconstr Surg* 2001;108:1624-1638.
7. Tamai S, Michon J, Tupper J, Fleming J. Report of IFSSH Subcommittee on Replantation. Microsurgical Committee. *J Hand Surg [Am]* 1983;8:730-732.
8. Chen ZW. Reattachment of traumatic amputations: a summing up of experiences. *China Med* 1967;5:392-397.
9. Medical Research Council (MRC). *Aids to the examination of the peripheral nervous system*. London: Her Majesty's Stationery Office; 1976.
10. Russell RC, O'Brien BM, Morrison WA, Pamamull G, MacLeod A. The late functional results of upper limb revascularization and replantation. *J Hand Surg [Am]* 1984;9:623-733.
11. Abrams RR, Ziets RJ, Lieber RL, Botte MJ. Anatomy of the radial nerve motor branches in the forearm. *J Hand Surg [Am]* 1997;22:232-237.
12. Revol MP, Lantieri L, Loy S, Guérin-Surville H. Vascular anatomy of the forearm muscles: a study of 50 dissections. *Plast Reconstr Surg* 1991;88:1026-1033.
13. Parry SW, Ward JW, Mathes SJ. Vascular anatomy of the upper extremity muscles. *Plast Reconstr Surg* 1988;81:358-363.
14. Hierner R, Berger A, Brenner P. Consideration on the management of sub-total and total macro-amputations of the upper extremity. *Unfallchirurg* 1998;101:184-192.
15. Fukui A, Tamai S. Present status of replantation in Japan. *Microsurgery* 1994;15:842-847.
16. Graham B, Adkins P, Tsai T-M, Firrel J, Breidenbach WC. Major replantation versus revision amputation and prosthetic fitting in the upper extremity: a late functional outcomes study. *J Hand Surg [Am]* 1998;23:783-791.